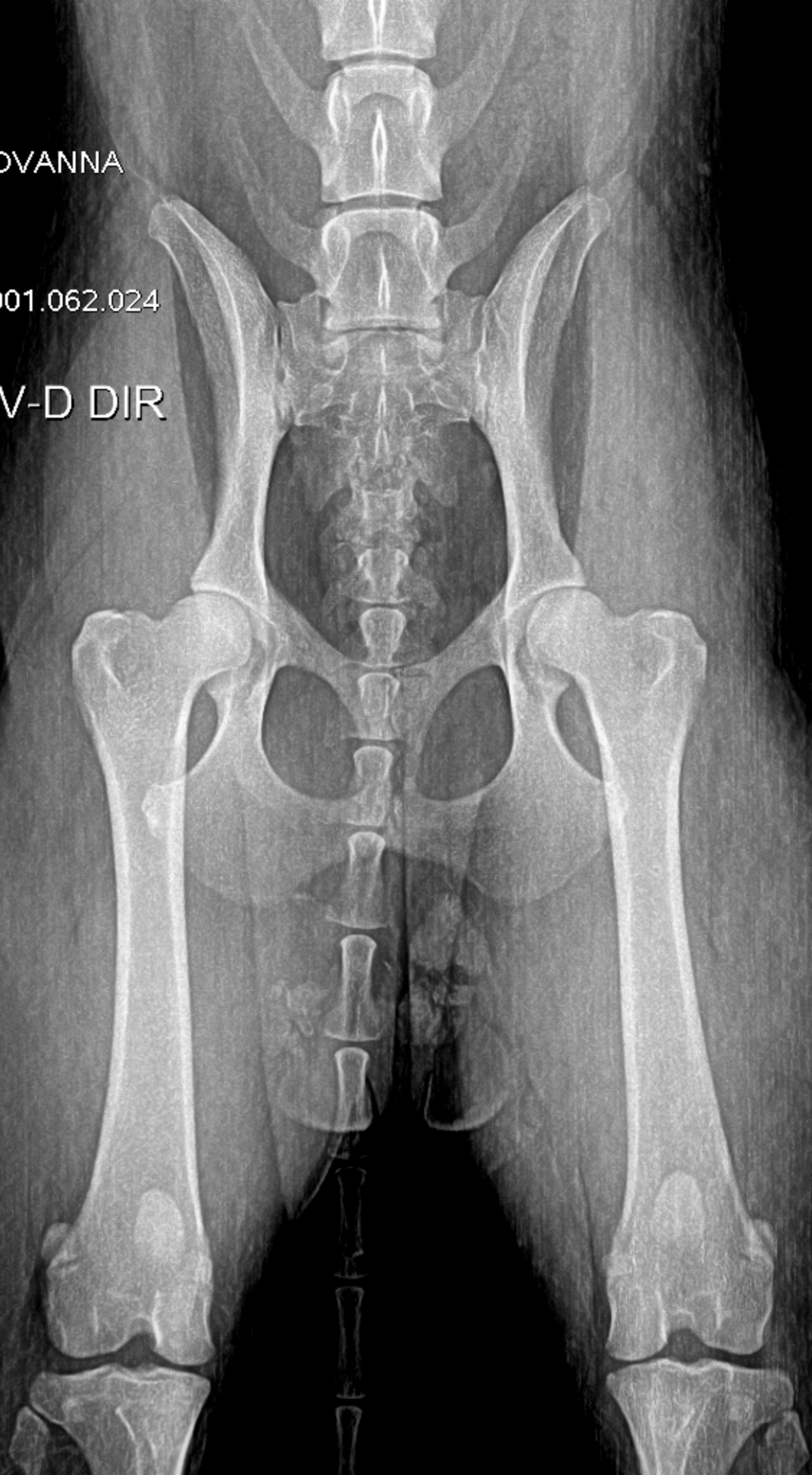


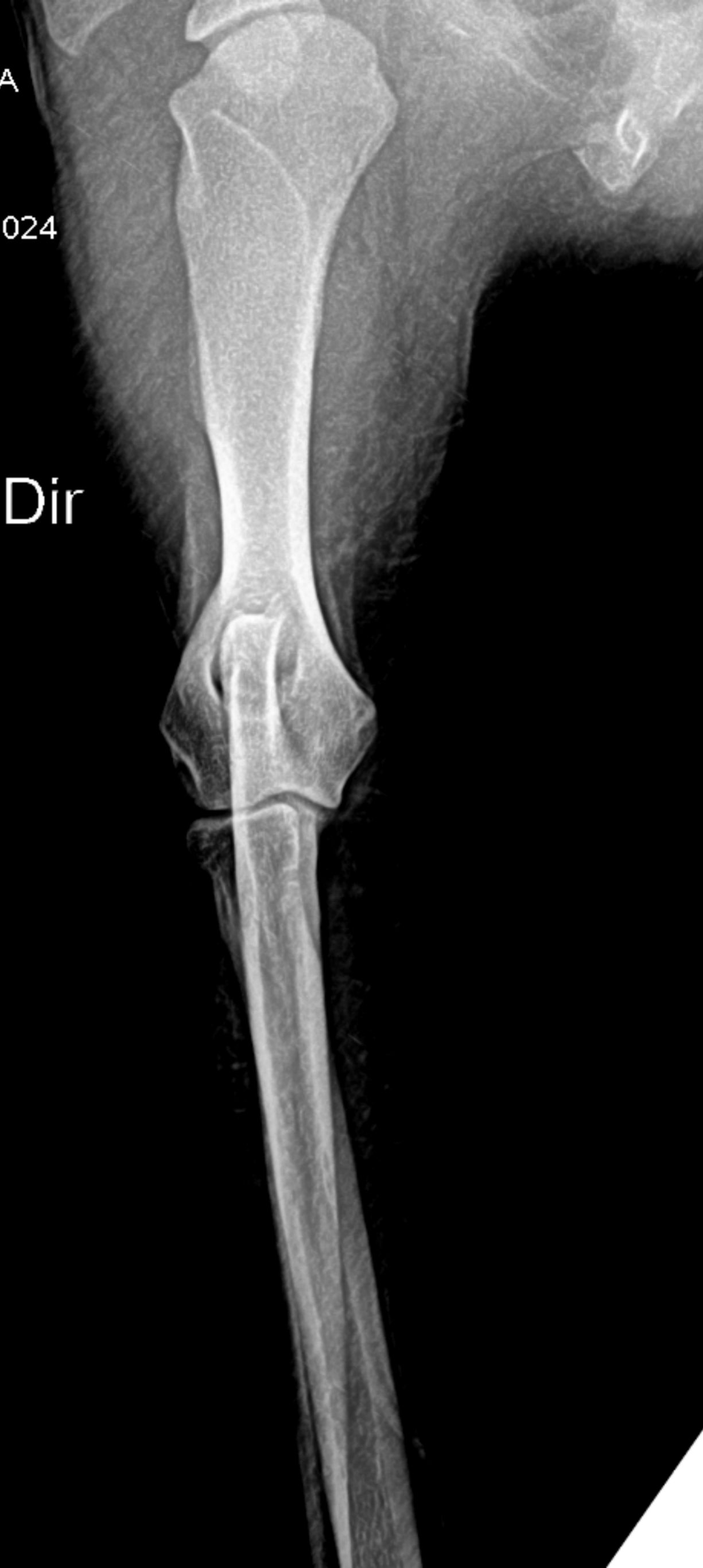BRITAIN BORDER GIOVANNA  
BORDER COLLIE  
FEMEA  
NASC. 19/10/2022  
MICROCHIP.900.233.001.062.024

V-D DIR



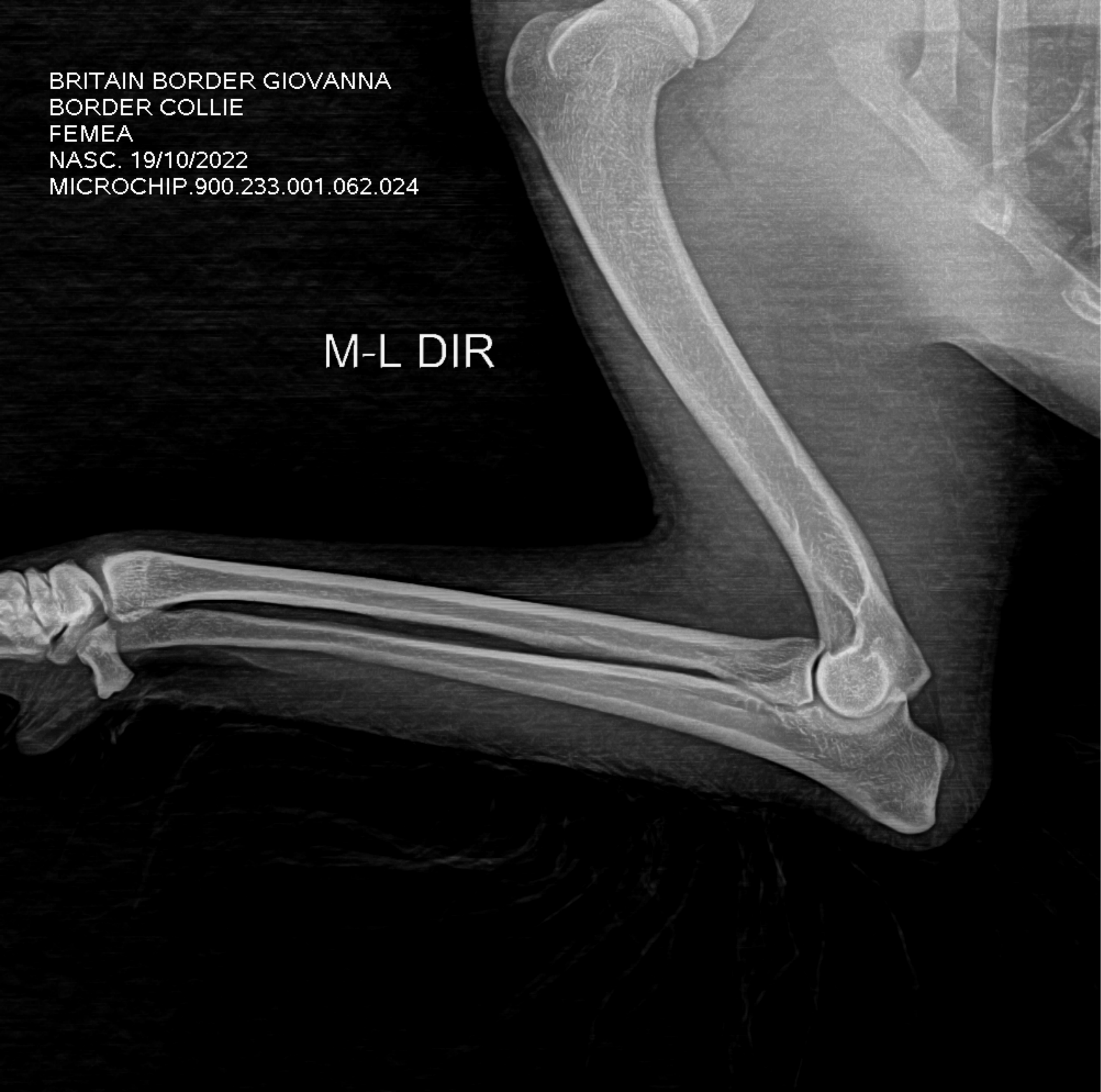BRITAIN BORDER GIOVANNA  
BORDER COLLIE  
FEMEA  
NASC. 19/10/2022  
MICROCHIP.900.233.001.062.024

Cr-Ca Dir



BRITAIN BORDER GIOVANNA  
BORDER COLLIE  
FEMEA  
NASC. 19/10/2022  
MICROCHIP.900.233.001.062.024

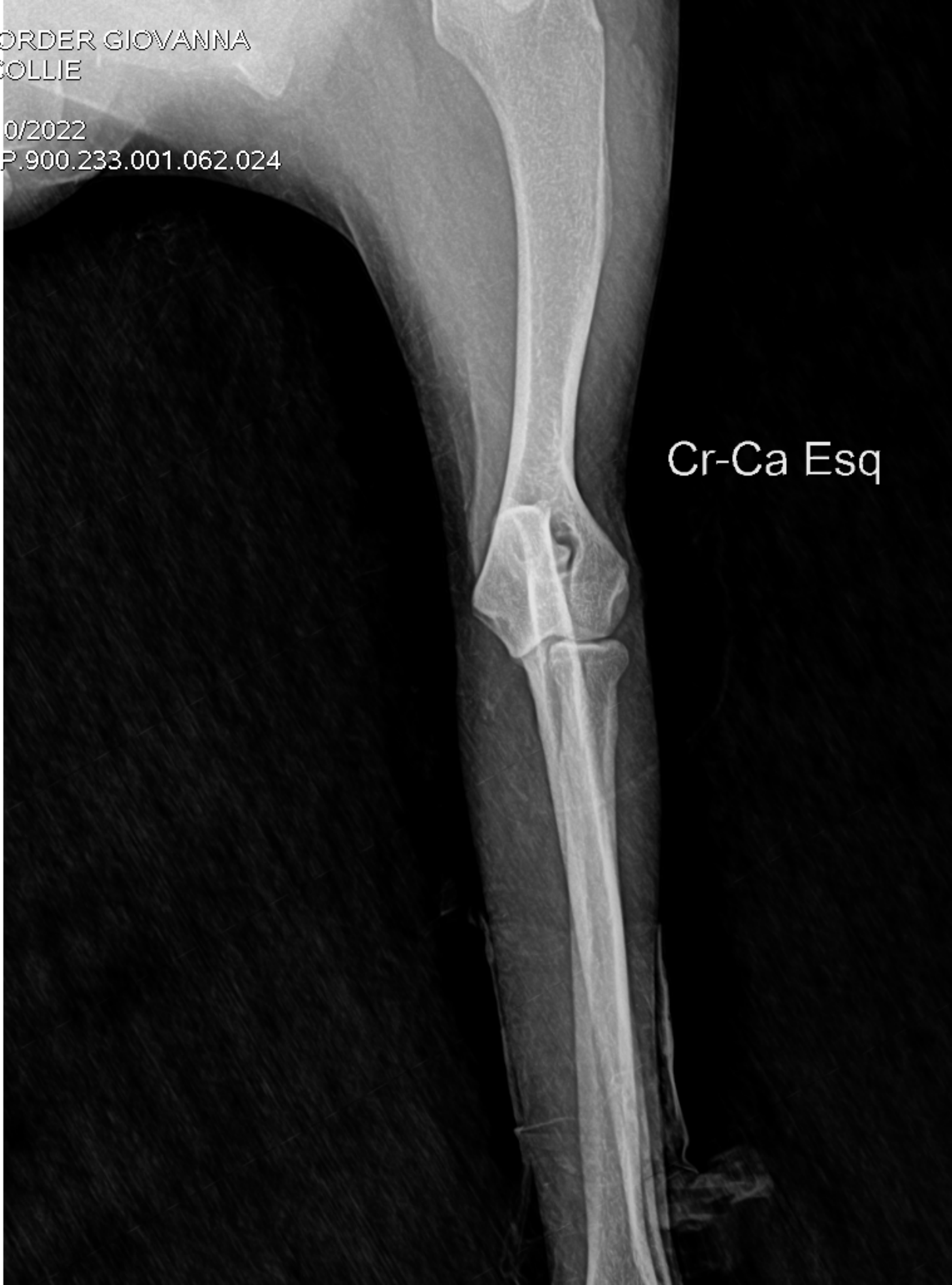
M-L DIR

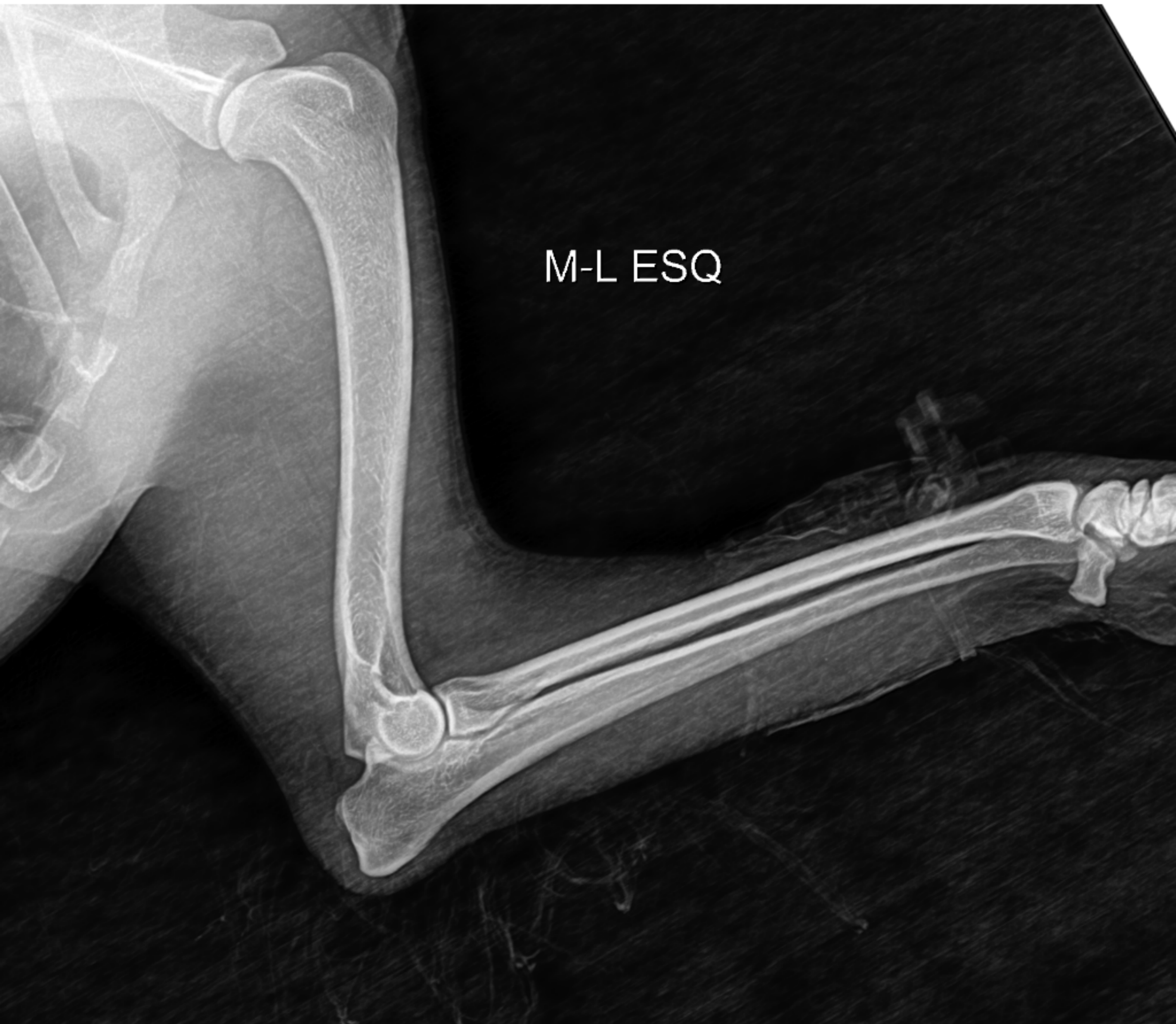




BRITAIN BORDER GIOVANNA  
BORDER COLLIE  
FEMEA  
NASC. 19/10/2022  
MICROCHIP.900.233.001.062.024

Cr-Ca Esq

A lateral radiograph of a dog's elbow joint. The image shows the distal humerus at the top, the ulna in the middle, and the radius at the bottom. The joint space is visible between the humerus and ulna. The bones are well-defined against a dark background. The text 'Cr-Ca Esq' is printed on the right side of the image.



M-L ESQ